



WOODWARD VETERINARY SURGERIES NEWS


AUTUMN 2011

- South Street, ASHBY ☎ 01530 412035
- 3 Burton Road, WOODVILLE ☎ 01283 210 858



Toxic Alert!

Permethrin spot-on poisoning in cats – cat owners beware!



Many over the counter, canine spot-on flea products bought from supermarkets and pet shops contain permethrins or similar products.

While these are perfectly safe for dogs, they should never be applied to cats, since permethrins are very poisonous to cats, causing fits and sometimes death. Whilst this is a year round hazard, a seasonal rise in fleas in the Autumn makes this a particular risk at this time of year. We have an excellent range of safe and effective flea products for your pets – please ask us to advise you on the best one for you!

Xylitol toxicity in dogs



Xylitol is a popular sugar substitute increasingly used as a sweetener in sugar-free chewing gum and other confectionery.

It can also be used as an ingredient (replacing sugar) in home baking. Whilst perfectly safe in humans, when products containing xylitol are eaten by dogs, it triggers a sudden release of insulin which causes a dramatic drop in blood sugar levels and can lead to liver damage as well. With an increasing number of products containing xylitol, this is something to be very aware of.

**24 HOUR
EMERGENCY SERVICE**
☎ 01530 412035


Autumn aches: is your pet affected?

WITH the cooler, damper Autumn weather upon us, now is the time when we all start to feel our aches and pains, and your pets are no exception. Look out for limps and difficulty in rising after rest



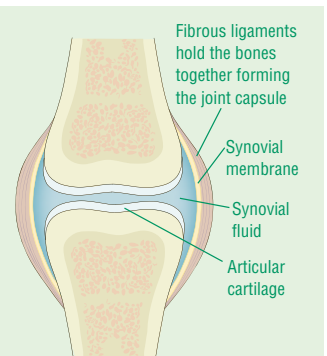
– these are signs that your pet may have joint stiffness and pain which can be made much worse by cold or damp weather.

The joints that are most susceptible to arthritis are those associated with limb movement; these joints are called synovial joints. The ends of the bones are covered by very smooth articular cartilage and the joints are also lubricated with synovial fluid – allowing friction free movement.

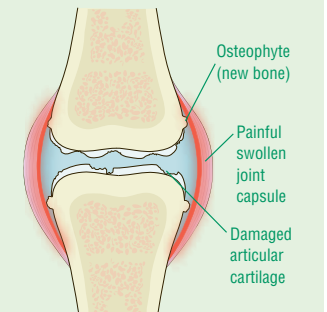


Arthritic joints typically show a progressive breakdown and thinning of the cartilage lining the ends of the bones and formation of secondary new bone around the joint. Affected joints usually appear stiff, swollen and painful. In the majority of cases, arthritis occurs secondary to a lifetime of wear and tear on the joints. Arthritis may also occur following joint trauma or due to a malformation of the joint.

The good news is that novel forms of medication together with weight control (which is also very important), can make a *huge* difference to the lives of affected pets. If your pet is showing signs of stiffness, come and see us for a check-up!



Healthy synovial joint with smooth articular cartilage



Arthritic synovial joint with damaged articular cartilage

Early socialisation of young pets



YOUR new pet has arrived and you've sorted out feeding, worms, fleas and vaccinations – but don't forget training and socialisation!

You may be surprised to learn that exposing young puppies to a range of sounds and experiences, in a controlled and gradual manner in the first three months of life (whilst

pups are naturally investigative), can be of help in *preventing* them developing fears, phobias and behavioural problems.

Even before your pup is fully vaccinated, try to familiarise him with safe environments such as your house, garden and car. Short car trips will introduce him to traffic and other loud noises. As soon as he has developed immunity from his vaccinations, it's important to get him out and about, to meet as many other dogs and pups as possible and to come across farm animals and other pets to build up his confidence.

If you would like further information on any aspect of puppy care, please ask any member of our practice team!

Firework phobia!

Unfortunately, despite your best efforts, some pets just hate fireworks. It is always advisable to keep pets indoors on firework night and this is especially important for those pets that are phobic about noise. Ensure nervous dogs have somewhere sheltered to hide. Keep the windows and curtains closed and try to have music or the TV on to help mask the sound.



Nervous pets may also benefit from a DAP diffuser to reduce anxiety. The diffuser needs to be plugged in 2-3 weeks *before* the event to have best effect. Noise desensitisation CDs, played over a long period of time, can also help.

Worms: a wriggly problem!



THERE are an array of worms which can affect dogs and cats, but for simplicity, these can be split into two basic groups – **roundworms** and **tapeworms**. A heavy worm infestation can cause a range of symptoms including vomiting, diarrhoea, loss of appetite, and weight loss. In addition, a new and serious threat to dogs comes in the form of **lungworm** – *Angiostrongylus vasorum* (see the article in the right hand column for details).

Roundworms are spaghetti like in appearance and live in the small intestines. Here they shed thousands of tiny eggs per day, which pass out in the faeces and contaminate the environment, where they can survive for several years (long after the faeces has broken down). Dogs and cats are then re-infected by inadvertently eating the eggs. The eggs also pose some risk to children if they are unwittingly swallowed. Puppies and kittens are often heavily infested with roundworms, ingesting roundworm larvae via their mother's milk.

Tapeworms live in the small intestines and consist of a head and a long flat segmented body. They shed small segments containing eggs which pass out in the faeces or which may be found around the tail area. As the segments break down, the eggs may then be eaten by an intermediate host; these include small rodents and fleas. Cats commonly catch and eat small rodents and both cats and dogs swallow fleas as they groom, thus re-infesting themselves with tapeworms.



It is important to note that just because you don't see any evidence of worms in your pet's faeces doesn't mean they are necessarily worm free since roundworm eggs are microscopic, and tapeworm segments can be hard to spot. The good news is that worms can be prevented by following a few simple rules: worm your pets regularly, use regular flea control, keep gardens clear of faeces, and when out and about, clear up mess and use appropriate bins. Additionally, encourage children to wash their hands properly after playing with pets or in the garden.

Please ask us to advise you on the most effective worm *and* flea control regime for your pet – contact us today for further information!



Typical roundworms in this case *Toxocara canis*



Tapeworm segments e.g. *Taenia taeniaeformis*



Both small rodents and fleas act as *intermediate* hosts for tapeworms.

Lungworm – a potential killer



DID you know that there is now a new and serious threat to **dogs** from the lungworm *Angiostrongylus vasorum*?

It is spread by intermediate hosts including **snails, slugs and frogs** which thrive in warm wet weather – so typical of our recent summers.



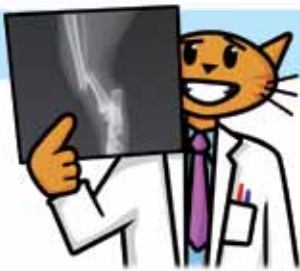What are the symptoms? In infected dogs adult lungworms live in the **pulmonary (lung) arteries and right ventricle of the heart**. Here they lay eggs, which hatch into *larvae* and which in turn migrate into the **airways of the lungs**. Affected pets may show a range of symptoms including coughing, reluctance to exercise, weight loss, fits, diarrhoea, and clotting problems.

So what is the lifecycle? The larvae that have migrated to the lungs are in turn coughed up, swallowed and passed out in the dog's faeces. As the faeces break down, the larvae are then eaten by **snails, slugs and frogs** (as mentioned above).

This is a problem for dog owners since dogs may unwittingly swallow infected snails and slugs (or their slime trails) whilst exploring parks and gardens. Once swallowed, the larvae migrate to the heart where they develop into adult worms and so the life-cycle is completed.

In addition to regular worming against roundworms and tapeworms, we also recommend regular treatment aimed at preventing lungworm – please let us advise you for the best treatment for your dog.

Amazing X-rays!

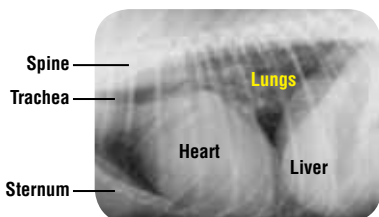


IT'S AN astounding fact that x-rays were discovered over 100 years ago – in 1895, and within a year of their discovery were being used clinically to diagnose and assess bone fractures. The really good news is that in modern day veterinary medicine, we can use x-rays to investigate a wide range of problems in pets. Although x-rays show up bones best of all (and are

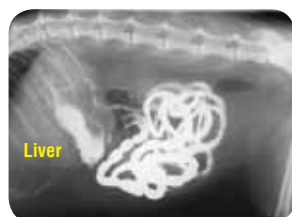particularly useful in diagnosing broken bones, arthritic changes and bone disorders), they are also used for looking at the size, shape and consistency of a number of other organs.

Chest radiographs (such as the example bottom left) allow us to assess the heart and lungs, whilst radiographs of the **abdomen** allow us to visualise internal organs such as the liver, stomach, intestines, kidneys and bladder. With x-rays, we can identify organs that have changed in appearance (for example the enlarged heart in the radiograph bottom left).

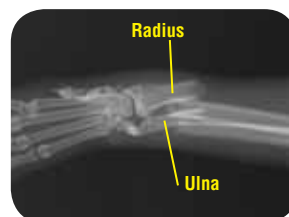As you can see, radiography allows us to “look inside” your pet, without having to do an operation and the information it gives us helps us to make a diagnosis in a huge range of conditions.



Chest radiograph of a dog with an enlarged heart and elevated trachea



Abdominal radiograph of a cat. Barium outlines the stomach and intestines



Radiograph of a dog with a fractured forelimb involving both radius and ulna bones.